

## PARA-AORTIC LYMPH NODE METASTASIS

---

**CYBERKNIFE®**  
At  *Community Regional Medical Center*

CyberKnife® Team:  
Radiation Oncologists: Douglas Wong, M.D., Ph.D., MPH  
Urologist: Greg Rainwater, M.D.  
Physicist: Georg Weidlich, Ph.D.  
CyberKnife Therapists: Jeff Wallace, RTT  
Valerie Cano, RTT  
CyberKnife Coordinator: Laura Valenzuela, RN, BSN, OCN  
CyberKnife Center: Community Regional Medical Center  
Fresno, CA

## PARA-AORTIC LYMPH NODE METASTASIS

### DEMOGRAPHICS

**Sex:** Male  
**Age:** 66 years  
**Histology:** Metastatic Renal Cell Carcinoma

### CLINICAL HISTORY

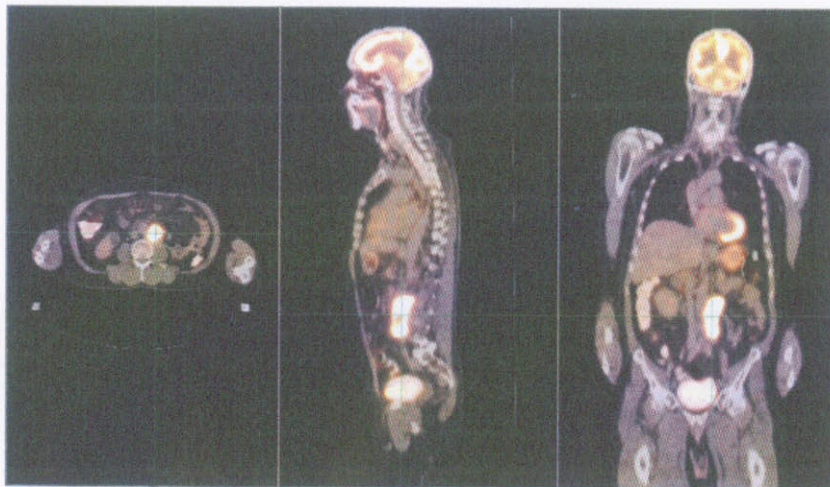
**Referred by:** Medical Oncologist  
**Past Medical History:** Stage IV renal cell carcinoma, treated by radical nephrectomy one year prior

### Case History

A 66-year-old male with a history of Stage IV renal cell carcinoma, treated with a left nephrectomy one year prior, presented with progressive left flank pain and findings of a large confluent left para-aortic lymph node mass on follow-up imaging studies. A CT-guided biopsy of the left para-aortic lymph node revealed metastatic carcinoma consistent with high-grade renal cell carcinoma. PET-CT scans revealed focal hypermetabolism in a region of confluent left para-aortic adenopathy, measuring 9.0 cm x 4.5 cm x 5.0 cm, with invasion of the adjacent psoas muscle (see Figure 1). At the time of the initial diagnosis of the renal cell carcinoma (Stage III, pT3N1M0) a radical nephrectomy had been performed to remove a 2-cm lesion involving the lower pole of the left kidney and a 5-cm mass in the mid-kidney that extended focally through the left renal capsule involving the perinephric fat. Lymph node sampling at the time of nephrectomy revealed one of four para-aortic lymph nodes positive for metastatic renal cell carcinoma. At the time a decision was made to follow these findings with PET-CT imaging.

### CyberKnife® Treatment Rationale

Renal cell carcinoma has typically been treated primarily with surgical resection and has not responded well to treatment by conventional radiation therapy because of the inability to deliver high, tumoricidal doses of radiation to the tumor safely. The location of this large para-aortic mass as well as its intimate relationship with adjacent vasculature made surgical resection an unlikely option in this case. Treatment was attempted with multiple tyrosine kinase inhibitors to shrink the tumor but this therapy was not tolerated. CyberKnife® radiosurgery was chosen to allow delivery of high doses of radiation in a conformal manner to spare the adjacent critical structures while still delivering doses high enough to achieve tumor control. The CyberKnife System has successfully treated primary renal cell carcinomas,<sup>1</sup> as well as spinal metastases from renal cell carcinoma,<sup>2</sup> while preserving the surrounding tissue and critical structures.



*Figure 1. Pretreatment PET-CT scans revealed high FDG uptake in the region of the confluent left para-aortic adenopathy measuring 9.0 cm x 4.5 cm x 5.0 cm, with invasion of the adjacent psoas muscle.*

**TREATMENT DETAILS**

**Treatment Volume:** PTV=99.9 cm<sup>3</sup>  
**Imaging Technique(s):** CT  
**Rx Dose & Isodose:** 24 Gy to 80%  
**Dose and Fractions:** 8 Gy x 3 fractions  
**Number of Beams:** 174

**Number of Fiducials:** 5  
**Treatment Time:** 120 minutes/fraction  
**Tracking Method:** Synchrony  
**Collimator(s):** 25 mm  
**Tumor Coverage:** PTV=97.7%

**Planning Process**

The patient was prepared for treatment planning by implanting five fiducials into the periphery of the tumor. A vac lock bag and knee sponge were used for immobilization. Contours of the GTV, PTV, right kidney, adjacent bowel and spinal canal were generated on the imaging studies. To protect adjacent small bowel, the PTV was deliberately made smaller than the GTV, accepting a dose gradient across the anterior rim of the GTV. A conformal treatment plan was developed using the MultiPlan® Treatment Planning System to cover 97.7% of the PTV and 86.2% of the GTV (see Figure 2).

**Treatment Delivery**

The patient received 24 Gy delivered in three fractions of 8 Gy over three days. The treatment was delivered to a volume of 99.9 cm<sup>3</sup> (PTV), using 174 beams and a 25-mm collimator. The 80% isodose line provided 97.7% coverage of the PTV. The three outpatient treatments were accompanied by mild nausea that was relieved with oral compazine.


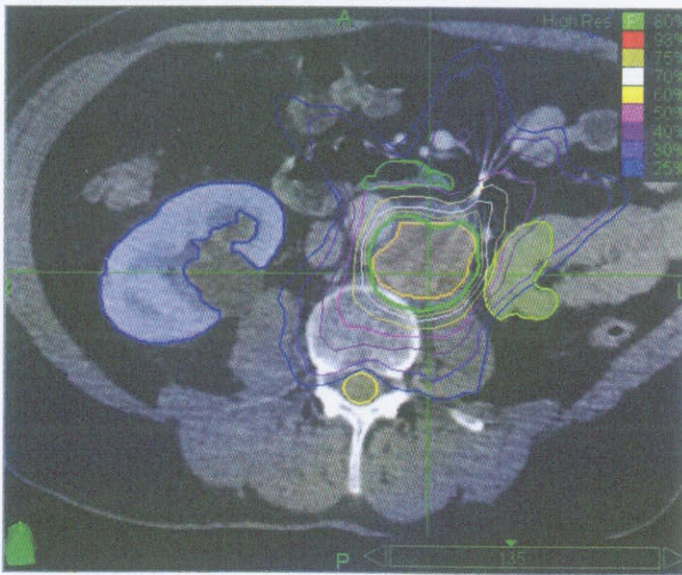


Figure 2. Left panel shows an axial view of the treatment plan developed using the MultiPlan® System. The 80% prescription isodose line is shown in green. Note high conformality and sparing of critical structures. The right panel shows a 3-D rendering of treatment beams as selected by the optimization algorithm.